


AVAILABLE SIZES




epicite® RESCUE
10cm x 10cm
10 Pcs
Item no.: 804005



epicite® RESCUE
15cm x 20cm
10 Pcs
Item no.: 804006



epicite® RESCUE
20cm x 20cm
5 Pcs
Item no.: 804007



epicite® RESCUE
FACE MASK
5 Pcs
Item no.: 804008



EPIB_0108_0825



ABOUT US

epicite® RESCUE is manufactured by JeNaCell, an Evonik company, in Germany, at highest quality standard. JeNaCell is a specialist in advanced wound care with a portfolio of medical products for the treatment of burns and chronic wounds.



VERTRIEB DEUTSCHLAND

asclepios

Medizintechnik

info@asclepios.de

07685 90 93 33

HERSTELLERINFORMATIONEN

JeNaCell GmbH - An Evonik company

Göschwitzer Str. 22

D-07745 Jena

Find more information

www.epicite.com/en/rescue

LEARN MORE



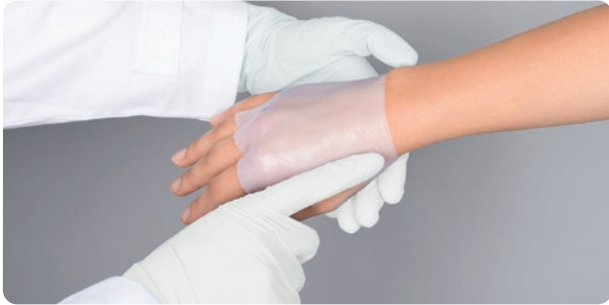HYDRO ACTIVE WOUND DRESSING

STERILE DEVICE
MADE IN GERMANY

THE TRUSTED ALLY IN ADVANCED BURN TREATMENT

Composed of Biosynthetic Cellulose and Saline Solution

epicite® RESCUE is an advanced wound dressing tailored to establish an optimal moist wound environment, promoting the effective healing of burns and acute wounds. With more than 95% water content, the nature-identical biomaterial cools damaged tissue immediately, reduces pain, and promotes successful wound healing. With years of expertise, the epicite® wound dressing family employs a dressing technology that has consistently delivered clinically proven, trustworthy results.



epicite® RESCUE is indicated for the treatment of:

- First- and second-degree burns
- Surgical wounds
- Skin grafts
- Split skin grafts

ADVANTAGES



1 Pain relief + mild cooling effect

Offering an immediate cooling effect ¹ and clinically proven to relieve pain ²⁻⁴, epicite® RESCUE helps to enhance patient comfort and acceptance of treatment.

2 Moist wound environment and promotion of wound healing

epicite® RESCUE effectively delivers moisture, and sustains an ideal moist wound environment and dermal hydration essential for successful wound healing ^{3,5,6}.

3 Effective wound cleansing

epicite® RESCUE supports autolytic debridement, ensuring effective wound bed preparation crucial for healing ⁵.

4 Reduced dressing interventions

epicite® RESCUE can remain on the wound until reepithelialization for up to 14 days, leading to less dressing changes in comparison to standard of care ^{2,3,6,7}.

This reduces the need for general anesthesia, minimizes pain and discomfort, lowers costs, and decreases the risk of infection ^{7,8}.

5 Shorter hospital stay

epicite® RESCUE may enable earlier patient discharge by several days, decreasing maintenance efforts compared to standard procedures and enhancing cost efficiency ^{2,6-8}.

CLINICAL REFERENCES

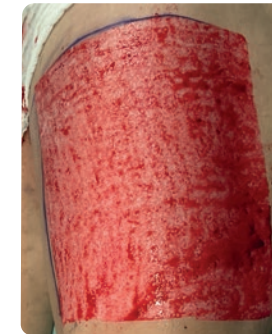1. Holzer, J.C.J., Tiffner, K., Kalnz, S., Reisenegger, P., Bernardelli de Mattos, I., Funk, M., Lemarchand, T., Laaff, H., Bal, A., Birngruber, T., Kolzbeck, P., Kamolz, L.-P., 2020. A novel human ex-vivo burn model and the local cooling effect of a bacterial nanocellulose-based wound dressing. *Burns* 46, 1924-1932. <https://doi.org/10.1016/j.burns.2020.06.024>
2. Luca-Pozner, V., Nischwitz, S.P., Conti, E., Lipa, G., Ghezal, S., Luze, H., Funk, M., Remy, H., Qassemayr, Q., 2022. The use of a novel burn dressing out of bacterial nanocellulose compared to the French standard of care in paediatric 2nd degree burns - A retrospective analysis. *Burns* 48, 1472-1480. <https://doi.org/10.1016/j.burns.2021.11.019>
3. Resch, A., Staud, C., Radtke, C., 2021. Nanocellulose-based wound dressing for conservative wound management in children with second-degree burns. *International Wound Journal* 19, 478-486. <https://doi.org/10.1111/iwj.13548>
4. Schiefer, J.L., Aretz, G.F., Fuchs, P.C., Bagheri, M., Funk, M., Schulz, A., Daniels, M., 2022. Comparison of wound healing and patient comfort in partial-thickness burn wounds treated with SUPRATHEL and epicithydro wound dressings. *International Wound Journal* 19, 782-790. <https://doi.org/10.1111/iwj.13674>
5. Zahel, P., Beekmann, U., Eberlein, T., Schmitz, M., Werz, O., Kralisch, D., 2022. Bacterial Cellulose—Adaptation of a Nature-Identical Material to the Needs of Advanced Chronic Wound Care. *Pharmaceuticals* 15, 683. <https://doi.org/10.3390/ph15060683>
6. Cattelaens, J., Turco, L., Berclaz, L.M., Huelisse, B., Hitzl, W., Vollkommer, T., Bodenschatz, K.J., 2020. The Impact of a Nanocellulose-Based Wound Dressing in the Management of Thermal Injuries in Children: Results of a Retrospective Evaluation. *Life* 10, 212. <https://doi.org/10.3390/ife10090212>
7. Renkert, M., Günter, F., Mohr, C., Maurer, K., Klinke Petrowsky, M.M., Boettcher, M., Elrod, J., 2024. Nanocellulose significantly reduces number of anesthetics, hospital days, and in-patient dressing changes compared to PU-Foam Dressing: A prospective cohort study in children. *Burns* 50, 107206. <https://doi.org/10.1016/j.burns.2024.07.010>
8. Maurer, K., Renkert, M., Duis, M., Weiss, C., Wessel, L.M., Lange, B., 2022. Application of bacterial nanocellulose-based wound dressings in the management of thermal injuries: Experience in 92 children. *Burns* 48, 608-614. <https://doi.org/10.1016/j.burns.2021.07.002>

CLINICAL RESULTS

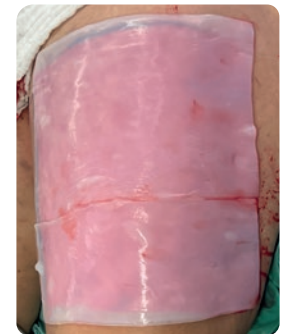Case: Skin Graft Donor Site

A 41-year-old male underwent reconstruction using a radial forearm flap. The skin graft donor site for covering the forearm donor area was harvested from the thigh and protected with epicite® and secondary dressings. The wound remained infection-free throughout the hospital stay and showed no abnormalities during dressing changes. On postoperative day 14, two-thirds of the epicite® was painlessly removed, revealing non-irritated wound conditions with fine pink epithelialization. The remaining epicite® was removed on day 15 prior to discharge. At the follow-up one week later, the donor site was fully healed with no signs of infection or secretion.

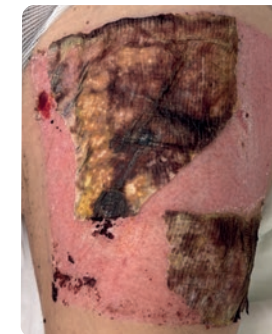Images with kind permission of Prof. Lars-Peter Kamolz, Head of Division Plastic, Aesthetic and Reconstructive Surgery, Med Uni Graz, Austria



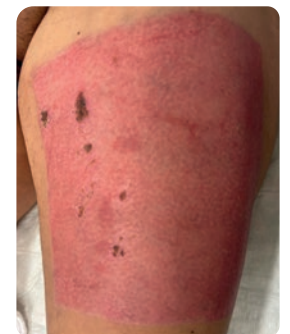Day 0 – Skin Graft Donor Site



Day 0 – Donor Site covered with epicite® RESCUE



Day 14 – Partial removal of the epicite® RESCUE wound dressing one day prior to discharge



Day 21 – Follow-up examination 7 days after removal of the epicite® RESCUE dressing